

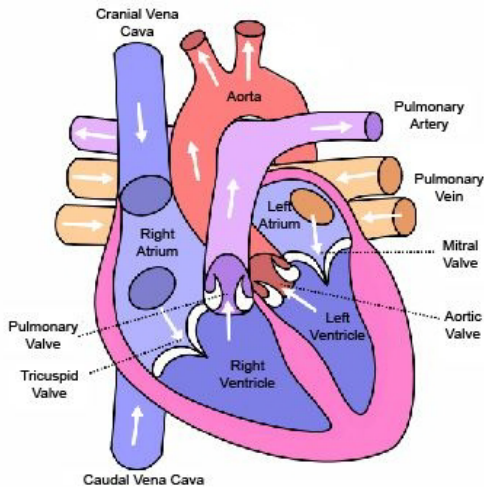


## Animal Emergency & Referral Associates

1237 Bloomfield Avenue • Fairfield, NJ 07004  
973.226.3282 • Fax 973.364.0004 • animalerc.com

**Gordon D. Peddle, VMD,  
DACVIM (Cardiology)**  
Director of the Cardiology Section,  
AERA Internal Medicine Department

## Pulmonary Hypertension



Pulmonary hypertension (PH) is a term used to describe an abnormally elevated pulmonary artery pressure. In essence this means that the blood pressure within the arteries in the lungs is elevated. This is a separate disease entity from *systemic hypertension* which describes elevated blood pressure in the rest of the body. This elevated pulmonary artery pressure leads to decreased blood flow to the lungs and increases the workload of the right side of the heart. It also results in structural changes to the pulmonary artery and right heart chambers.

### What causes pulmonary hypertension?

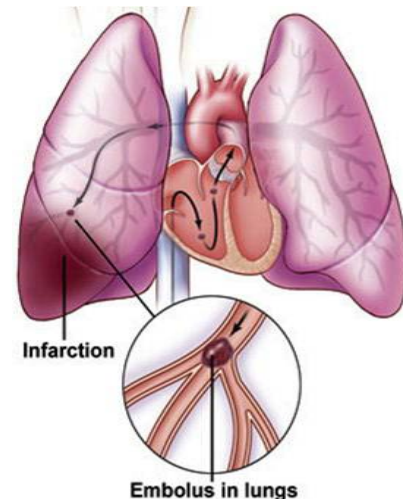
Causes of pulmonary hypertension are numerous but in dogs there are five major causes appreciated clinically:

- Chronic bronchial/lung disease
  - Often seen in small breed dogs
- Pulmonary thromboembolism (PTE)
  - Blood clots in circulation that lodge in blood vessels in the lungs
  - Can occur secondary to a variety of immune-mediated, endocrine, organ dysfunction, or neoplastic (cancerous) diseases
- Heartworm disease
- Chronic left-sided heart disease
- Intracardiac or arteriovenous shunts (usually congenital)

In a significant number of cases, the underlying cause is not identified or only suspected.

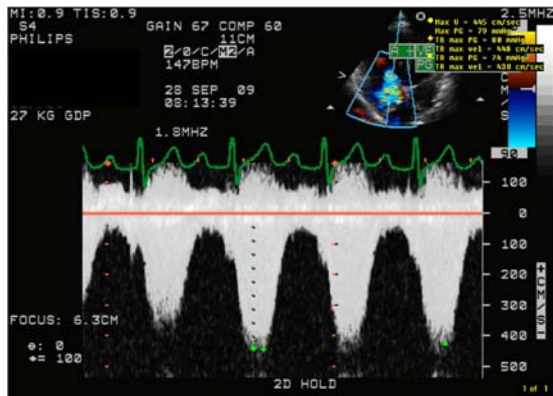
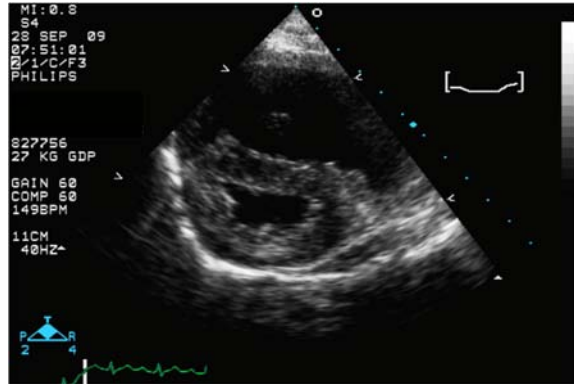
### Clinical signs

Clinical signs of pulmonary hypertension usually involve increased respiratory effort or distress, coughing, exercise intolerance, collapse or fainting episodes but can also manifest as progressive lethargy. PH can lead to right-sided heart failure which would most likely appear as abdominal distension.



## Diagnosis

Diagnosis of PH in humans usually requires cardiac catheterization and direct measurement of pulmonary artery pressures and resistance. This is rarely performed in dogs and cats because often these patients are in serious condition and it will require heavy sedation or general anesthesia. Diagnosis of PH in veterinary medicine, therefore, is most effective via an echocardiogram (cardiac ultrasound) performed by a board-certified veterinary cardiologist. The echocardiogram assesses structural changes to the heart as well as blood flow abnormalities that allow for indirect estimation of pulmonary artery pressure. Disease is classified as mild, moderate, or severe and can worsen over time.



A complete workup for the underlying cause of PH is warranted once diagnosis is confirmed, including bloodwork/urinalysis, radiographs (x-rays), and abdominal imaging.

## Treatment

Dogs with severe pulmonary hypertension often require immediate hospitalization and oxygen therapy while diagnostic workup and treatment are performed. Treatment is aimed at identifiable, underlying causal conditions and

may include bronchodilators or anti-thrombotic drugs. In most cases (regardless of cause), powerful drugs that vasodilate the pulmonary arterial system are required to improve clinical condition. The drug most commonly used is Sildenafil (Viagra). Although echocardiographic parameters often do not significantly change with treatment, patients are often highly clinically responsive to the medication. Cialis (Tadalafil) is occasionally used as a substitute for Sildenafil. Therapy for PH is life-long.

## Prognosis

The long term prognosis for PH is generally guarded to poor, but patients often do well in the short term and maintain a good quality of life with continued therapy. It may be a few days or more in the hospital before they begin to show a response to therapy, however.